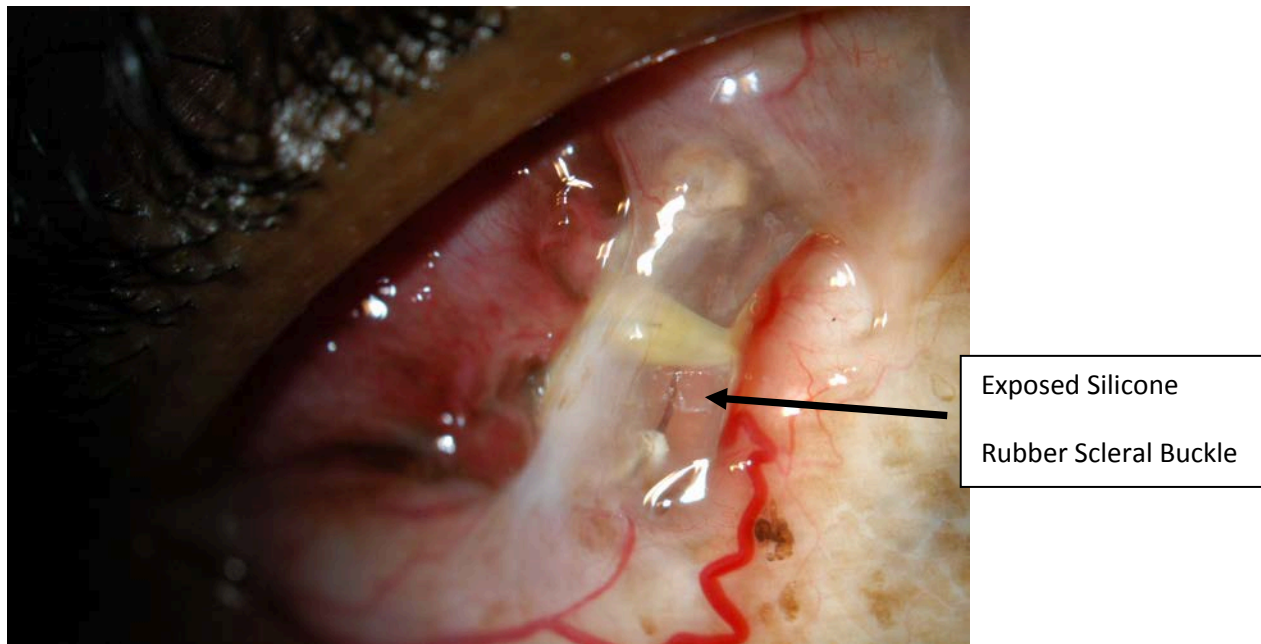


What You Should Know About Exposed and Infected Scleral Buckles

By David J. Browning, MD, PhD

To repair a retinal detachment, a common method used is to suture a silicone rubber strip to the surface of the eye (the sclera). This indents the wall of the eye under the retinal tear, in effect closing the hole, and allowing the eye to pump out the fluid under the retina. Occasionally after surgery, the conjunctiva overlying the silicone rubber element breaks down, exposing the sclera buckle. Infected, exposed sclera buckles occur after approximately two percent of retinal detachment repairs using sclera buckles.(1) In most cases, the sclera buckle is infected, most commonly with staphylococcus epidermidis, a bacteria found on skin.(2) Once this occurs, it is usually impossible to cure the infection with antibiotic drops or pills. The bacteria secrete a biofilm that surrounds the sclera buckle, preventing adequate penetration of antibiotics.(3) Exposed and infected sclera buckles are often associated with a red, watery eye that produces mucous. Such a case is shown in the figure below. In most cases, the sclera buckle must be removed, usually by a short operation. Rarely, the exposed sclera buckle can be removed in the office.



Once the exposed, infected sclera buckle has been removed, the infection quickly clears. However, in 17% of cases a the retinal detachment recurs, and another procedure must be done to reattach the retina.

After reading this information, If you would like to learn more about exposed and infected scleral buckles, an excellent resource is the Pubmed site on the National Library of Medicine web page at the following link:

<http://www.ncbi.nlm.nih.gov/entrez/query.fcgi>.

Updated 6-16-2012

Reference List

- (1) Weissgold DJ, Millay RH, Bochow TA. Rescue of exposed scleral buckles with cadaveric pericardial patch grafts. *Ophthalmology* 2001; 108:753-758.
- (2) Ulrich RA, Burton TC. Infections following scleral buckle procedures. *Arch Ophthalmol* 1974; 92:213-215.
- (3) Asaria RHY, Downie JA, McLaughlin-Borlace L, et al. Biofilm on scleral explants with and without clinical infection. *Retina* 1999; 19:447-450.