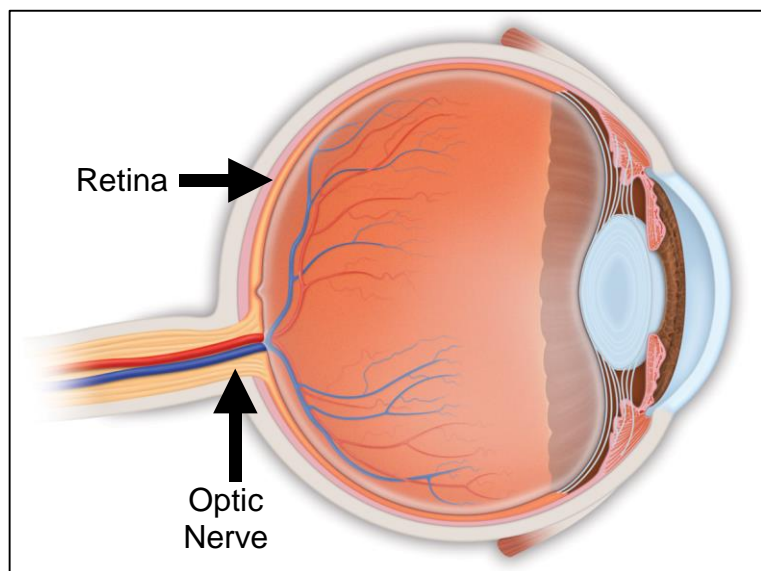


# What You Should Know About Branch Retinal Artery Occlusion

*David J. Browning MD, PhD*

A branch retinal artery occlusion is a blockage of a small artery in the retina, the lining of the back of the eye. This lining receives the light focused by the lens of the eye much as the film in a camera receives the light focused by the camera lens. The retina is nerve tissue, generating a signal in response to the light focused on it. This signal travels to the brain through the optic nerve as shown in Figure 1.



**Figure 1. Anatomy of the Eye Interior**

Like all nervous tissue, the retina requires large quantities of oxygen delivered by the bloodstream in order to function properly. Interruption of blood supply even for a few minutes impairs vision, and unless the blood supply is restored within 90 minutes, permanent damage to the retina with loss of part of the visual field results. A branch retinal artery occlusion is analogous to a stroke of the brain, the difference being that the function impaired is vision rather than movement of muscles, ability to speak, or some other brain function. Branch retinal artery occlusions are painless and cause sudden visual loss in one eye.

## What Causes Branch Retinal Artery Occlusions?

Branch retinal artery occlusions are caused by emboli, particles which travel in the bloodstream and lodge in a small artery, blocking its bloodflow. The most common blocking particles are pieces of cholesterol from plaques lining large arteries of the chest and neck. Less commonly the particles may be clumps of platelets, which build up on such plaques or sometimes pieces of calcium breaking off diseased heart valves. The factors that lead to cholesterol deposits in arteries or to valvular heart disease are thus the underlying risk factors for branch retinal artery occlusions. Most patients suffering branch retinal artery occlusions are over the age of 60. When they occur in younger patients, the possibility of blood clotting disorders or congenital heart abnormalities must be investigated.

## How Are Branch Retinal Artery Occlusions Discovered?

Typically an affected patient has sudden, painless loss of vision in one eye, which brings him to the ophthalmologist. The pupils are dilated and the occlusion can be recognized as a pale area of the retina. Sometimes the particle blocking the artery is visible. Figure 2 illustrates such a situation.

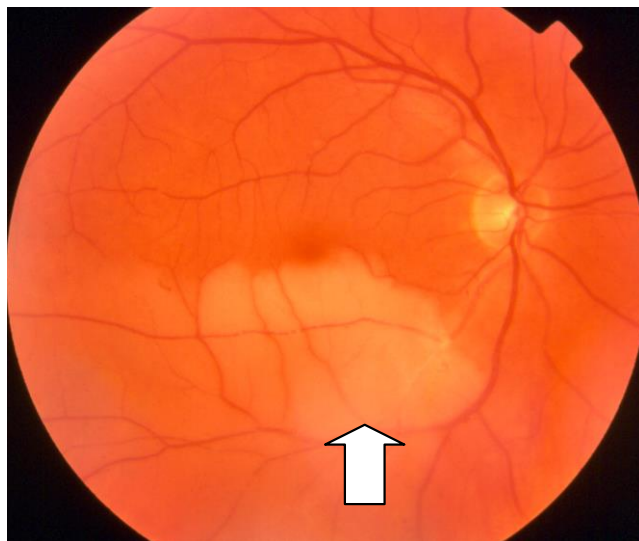

Figure 2. Eye with BRAO

## What Should Be Done For Branch Retinal Artery Occlusions?

Patients with branch retinal artery occlusion need to be evaluated for atherosclerosis (cholesterol plaques) of the major vessels of the chest and

neck. A carotid doppler and ultrasound study are done by a radiologist. An echocardiogram is performed to check for calcification of heart valves or congenital heart wall defects. For younger patients and patients with reasons to be suspicious, blood testing for clotting abnormalities are done, such as a test of the level of serum homocysteine.

### **What Is the Follow-up Care?**

If the patient is examined shortly after the occlusion, the ophthalmologist may attempt to dislodge the embolus from its position blocking the artery. Ocular massage may be tried, and in rare cases YAG laser treatment of the embolus, in an attempt to break it up. There is no proof that any treatment is effective in a general sense, but anecdotes of successful intervention have been printed in the medical literature. Sometimes the patient is started on aspirin to reduce the chance that platelets will clump on cholesterol plaques in the walls of large arteries. Sometimes stronger blood thinners such as warfarin are prescribed if a tendency to blood clotting is determined to exist. Rarely patients may need an operation called endarterectomy to clean out the large arteries in the neck. Consultation with a vascular surgeon is required to make these decisions. If the patient has diabetes, hypertension, or high cholesterol and lipids, then these conditions need to be optimized. Smokers should quit with the help of medicines, support groups, and other aids.

### **What is the Prognosis?**

Most patients with branch retinal artery occlusion involving the center of vision improve to a degree, but not completely. Eighty percent of patients eventually end up with visual acuity in the involved eye of at least 20/40, but almost all patients will notice that certain parts of the visual field are missing. The area of the missing spot may decrease over the first three months as the border zones of the affected retina regain health. The central dead zones in the involved retina do not regenerate, explaining the residual permanent visual deficit.

After you read this document, if you have further questions, please visit my website at [www.retinareference.com](http://www.retinareference.com). Another excellent resource for medical literature is Pubmed, on the National Library of Medicine website, accessible at [www.pubmed.com](http://www.pubmed.com).

Updated 4-28-2018