

What You Should Know About Blunt Trauma to the Eye: Commotio Retinae, Hyphema, Lens Dislocation, Vitreous Hemorrhage, Retinal Breaks, and Early and Late Glaucoma

By David J. Browning, MD, PhD

Blunt trauma to the eye can cause mild or serious injury, but in all cases a thorough examination is needed soon after the trauma to define the extent of damage. Serial subsequent examinations are necessary to detect possible late developing problems. Blunt trauma arises in situations such as fistfights, motor vehicle accidents, falls, and projectile injuries (paint ball and BB gun battles). Loss of vision is sudden and pain is common. Frequently, the patient initially seeks care at the emergency room or at an urgent care facility, where a primary care physician performs the best exam that he can. It is preferable, however, for an ophthalmologist to examine the patient soon after injury, because many of the examination methods and instruments necessary to assess the nature and extent of eye injuries are unfamiliar to emergency physicians. Although ocular examination is the first step, imaging techniques using CT scan, MRI scan, x-rays, and ultrasound may all be used depending on the nature of the injuries.

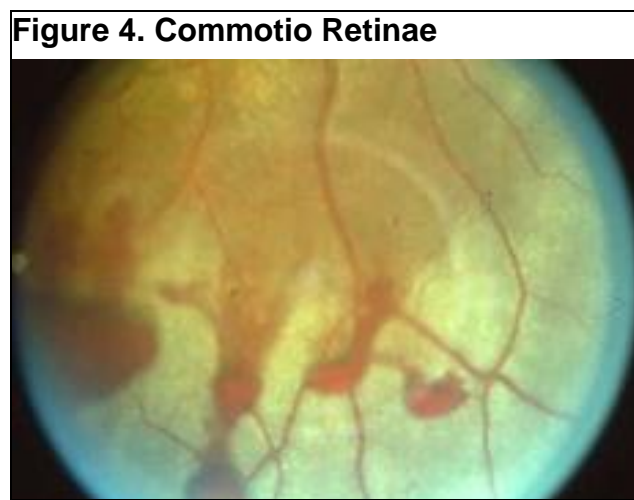
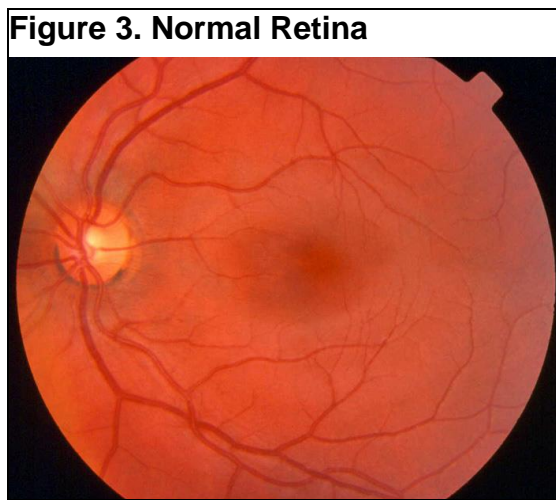
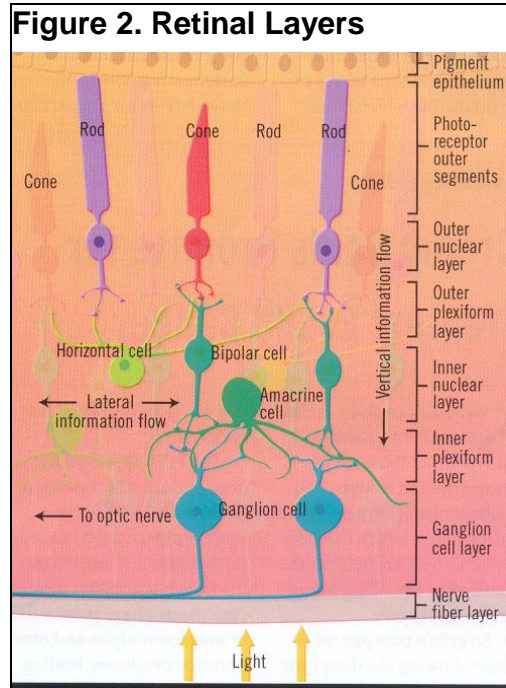
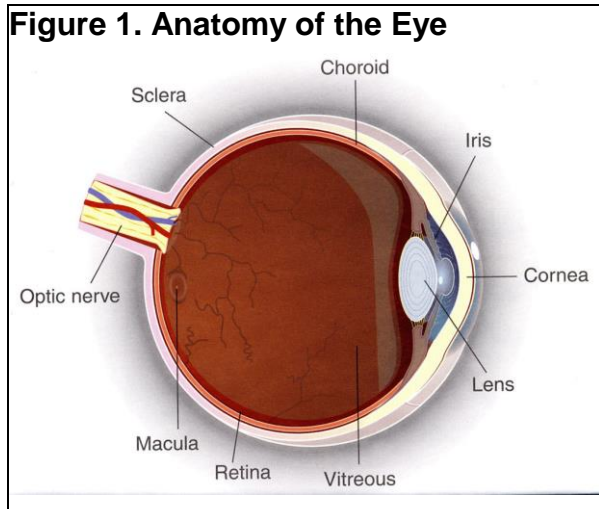
Commotio Retinae

Blunt trauma causes shearing of the photoreceptors of the retina with sudden impairment of visual acuity. This produces a shiny appearance to the retina that resolves in a few days. If the area of the retina involved includes the macula, a late macular hole may develop. These can be surgically repaired, but the prognosis is poorer than with non-traumatic macular holes because the underlying layer called the retinal pigment epithelium may also be damaged and scarred. Figure 1 shows the anatomy of the eye, figure 2 the layers of the retina, and figure 3 the appearance of commotio retinae.

Retinal Tears

Force transmitted through the vitreous gel can yank against the retina and tear it, or the retina may become atrophic from the blunt injury

and later tear. Thus a dilated fundus examination is necessary early after the injury, and similar examinations at intervals thereafter, especially if the patient experiences new flashing lights or floaters. If retinal tears are discovered, they are sealed with laser or cryo treatment to prevent retinal detachment.



Hyphema and Vitreous Hemorrhage

Blunt trauma can shear blood vessels at the base of the iris leading to a hyphema, an accumulation of blood in the anterior chamber between the iris and cornea. The blood may spill behind the lens to collect in the vitreous or retinal blood vessels may break and bleed into the vitreous. If not too severe, these hemorrhages often clear over time, from days to weeks. If the blood blocks the view to the retina, an ultrasound test may be needed to check for retinal tears or detachment. If retinal tears are found, or if eye pressure rises uncontrollably in association with hyphema, an operation may be required to remove the blood and/or seal the retinal breaks.

Dislocated Lens

The lens of the eye is suspended in position behind the iris by thin cables called zonules. Blunt trauma can break the zonules and the lens can fall out of position. If this should occur, the lens can be surgically removed, and depending on the other factors, a man-made intraocular lens may be sutured in its place, or the eye may be left without a lens with the intention of later fitting with a contact lens.

Late Glaucoma, Cataract, and Retinal Tears

Once the acute injuries are managed, there still remains the specter of late onset glaucoma, cataract, and retinal tears. Glaucoma is damage to the optic nerve caused by pressure in the eye. Cataract is a clouding of the normally clear lens of the eye. A regular schedule of eye examinations is necessary to detect glaucoma that may be asymptomatic. Cataract becomes apparent to the patient as slow, painless blurring of vision. Flashes of light or floaters may herald late retinal tears, and patients should heed these warning signs by coming in for an examination.

Final Comments

Blunt trauma to the delicate structures of the eye requires immediate and later ongoing care to minimize the adverse consequences. The key factor in raising the odds of the best outcome possible is education of the patient about what can happen, and what responses are needed.

After you read this document, if you have further questions, please visit my website at www.retinareference.com. Another excellent resource for medical literature is Pubmed, on the National Library of Medicine website, accessible at www.pubmed.com.

Updated 11/21/2017