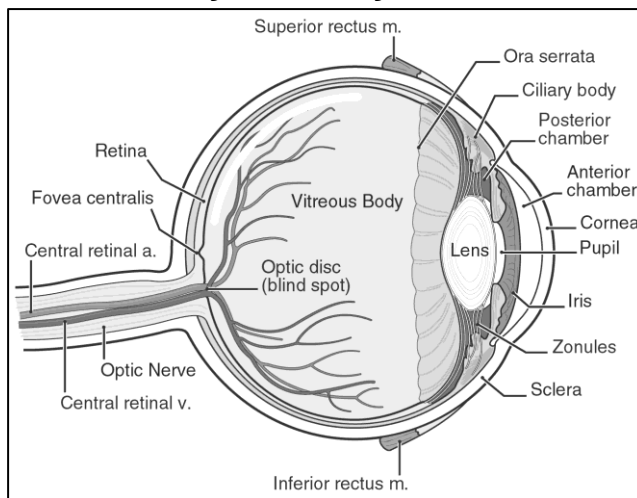


What You Should Know About Age Related Macular Degeneration

By David J. Browning, MD, PhD

Age related macular degeneration is a disease occurring in older people, which takes the central vision, but not the peripheral vision. It usually affects both eyes symmetrically, although one eye may be worse for a period. The target for the disease is the macula, the central part of the retina, which enables reading vision. The retina is the lining of nerve tissue at the back of the eye. Figure 1 identifies these parts of the eye.

Figure 1. Anatomy of the eye.



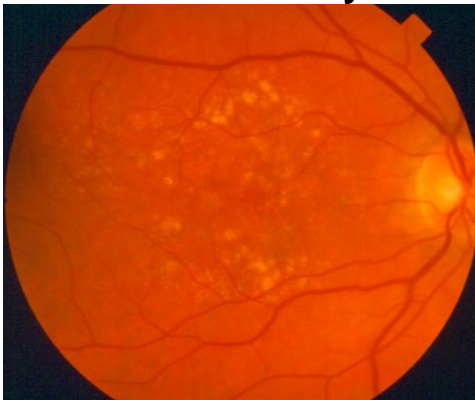
Two Types of Macular Degeneration

The two types of macular degeneration include dry and wet. Dry macular degeneration is much more common. In this condition, waste products from the retinal cells build up as yellow material under the retina. The retinal cells sitting on top of this waste material begin to die. The decrease in number of retinal cells causes patches of visual loss to develop. While looking at a word, for example, letters may begin to drop out of view. The waste material forms lumpy mounds under the macula, causing straight lines to look wavy. Dry macular degeneration takes vision slowly over many years. Figure 2 shows the inside of a healthy eye and Figure 3 shows an eye with dry macular degeneration.

Figure 2. Fundus of a Healthy Eye

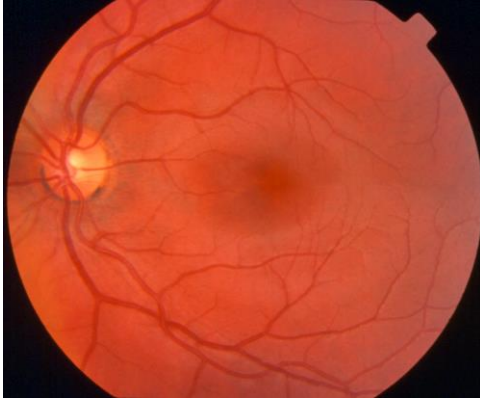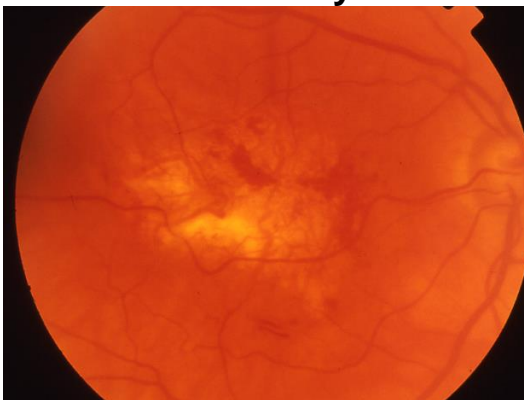


Figure 3. Fundus of an Eye with Dry Macular Degeneration



In wet macular degeneration, the blood vessels beneath the retina, which make up the choroid, begin to grow into the accumulated waste material. These blood vessels are abnormal and begin to leak serum, to bleed, and to incite scar tissue growth. All of these changes cause the overlying cells of the macula to die with loss of central vision. Wet macular degeneration takes vision rapidly. Figure 4 shows an eye with wet macular degeneration.

Figure 4 Fundus of an Eye with Wet Macular Degeneration



Causes of Macular Degeneration

Macular degeneration is a complex disease. A complete listing of all the contributing causes is not possible yet, but research is underway to identify them. At present, we know that there are risk factors for macular degeneration and protective factors against it, but we do not know how they work. There is a genetic component to the disease. A DNA mutation in the complement factor H gene, which leads to substitution of the amino acid tyrosine for histidine at position 402 in the complement factor H protein, increases one risk of advanced age related macular degeneration by 4-7 times. The search for other associated genetic mutations is ongoing. Some environmental risk factors include smoking, high blood pressure, and blue iris color. Some protective factors include being African-American, and maintaining a diet high in vitamin A, vegetable fat, green vegetables, and fish and nuts. (1)

This knowledge has led to the following advice for affected patients:

1. Increase consumption of dark leafy green vegetables, such as spinach and collard greens.
2. Increase consumption of oily fish, such as salmon, tuna, and sardines.
3. If one is a smoker, stop.
4. If one has hypertension, control it with exercise, weight loss, and if necessary, medication.

Use of Vitamin Supplements

A large national research study, called the Age Related Eye Disease Study 2 (AREDS2), has shown that visual loss in patients with macular degeneration is reduced by taking a supplementary multi-vitamin containing vitamins C (500 mg), E (400 international units); the minerals zinc (80 mg) and copper (2 mg); and the natural antioxidants lutein (10 mg) and zeaxanthin (2 mg). This multivitamin does not take the place of a general multivitamin such as Centrum Silver. The AREDS2 supplement is taken in addition to a general multivitamin.

Can Dry Macular Degeneration Change to Wet?

Yes. In fact, patients are advised to check a piece of paper with a pattern called an Amsler Grid, to help detect the change from dry to wet macular degeneration. The patient should check the Amsler grid daily, while wearing reading glasses. View the grid with one eye at a time, focusing on the dot at the center. Without searching, or looking away from the dot, ask yourself if the lines have any distortions or blurred out areas. If changes occur in what you see on this grid, you should come in for examination as a work-in patient. It is very important that you are seen promptly; so do not schedule a delayed appointment. Figure 5 shows an Amsler Grid. Figure 6 shows an example of a blurred out center of a clock caused by macular degeneration.

Figure 5





Figure 6



Treatments for Macular Degeneration

There is no treatment that cures any form of macular degeneration. Vitamin supplements have some beneficial effect in cases of dry macular degeneration. For wet macular degeneration, treatments to limit damage include various drugs injected into the eye on a periodic schedule. The injected drugs include Avastin, Lucentis, and Eylea. Rarely cold laser treatment is used. Other experimental therapies are in development.

The Role of Fluorescein Angiography and Optical Coherence Tomography

All of the treatments for macular degeneration depend on accurate characterization of the disease as dry or wet. Wet cases are further subdivided into several groups, including classic, occult, mixed, and scars. These categories are defined by examining photographs taken after food coloring is injected into the patient's vein. The pattern of the dye in the photographs of the eye helps to determine what type of treatment is preferable. Figure 7 shows an image from a normal fluorescein angiography and Figure 8 shows a fluorescein angiography of dry macular degeneration. Optical coherence tomography (OCT), a different type of photograph of the retina without any dye injection, helps to show if retinal swelling is occurring or resolving, and is useful in following the effects of treatments for wet macular degeneration. Figure 9 shows a typical printout from OCT. The retinal cross section shows cystic swelling arising from the abnormal blood vessels under the retina.

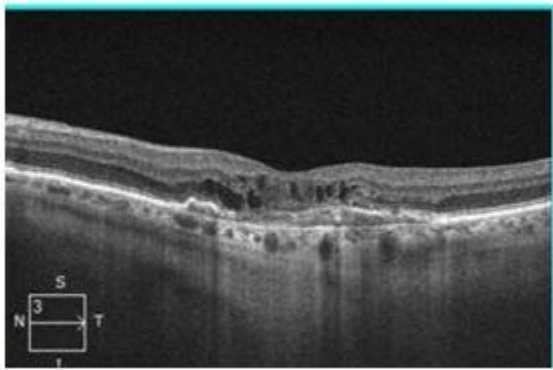
Figure 7 Normal Fluorescein Angiogram

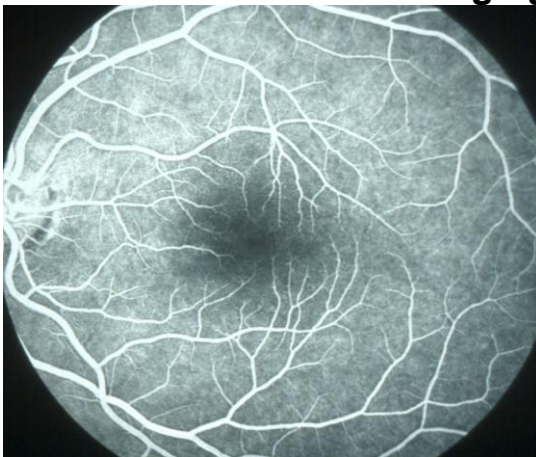

Figure 8 Fluorescein Angiogram in Dry macular degeneration

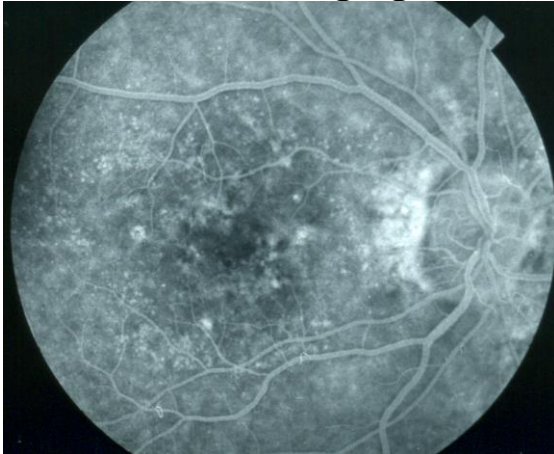

Figure 9 OCT in Wet Macular Degeneration



Final Comments

Treatments for macular degeneration are not generally going to restore vision to normal. Their purpose is to improve vision partially, and to slow the disease down or stabilize it. There is high hope that further research will result in better treatment options in the future.

After you read this brochure, if you have further questions, a resource for medical literature is Pubmed, on the National Library of Medicine website, accessible at www.pubmed.com.

References

1. Wu J, Cho E, Giovannucci EL, et al. Dietary Intakes of Eicosapentanoic Acid and Docosahexaenoic Acid and Risk of Age-Related Macular Degeneration. *Ophthalmol* 2017; 124: 634-643.

Updated 8-22-2017