

What You Should Know About Acute Retinal Necrosis

David J. Browning MD, PhD

What is Acute Retinal Necrosis?

Acute Retinal Necrosis, or ARN, is a rare devastating ocular disease caused by a reactivation of a previous infection of either the herpes simplex virus (HSV) or the varicella-zoster virus (VZV). Both HSV and VZV are common. In fact, testing has shown that over 90% of adults have had exposure to one of the many herpes virus families. However, the ARN syndrome is quite rare, occurring in 1 person out of every 1.58 million persons per year,¹ leading investigators to believe that there may be some genetic or environmental factors that predispose patients to developing the disease. Such genetic factors include HLA types which are “markers” on the surface of human cells. Evidence exists that people with the HLA-DQw7 antigen have a relative increased risk of developing the disease.²

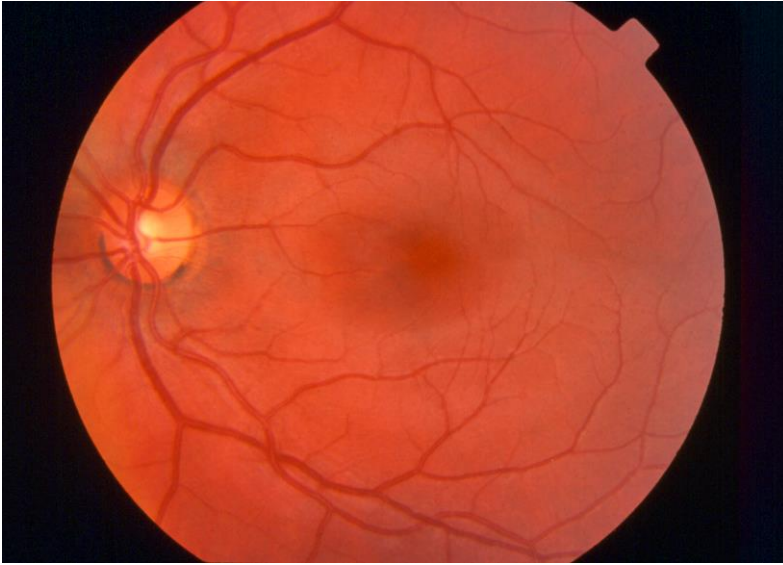
What are the symptoms of ARN?

A variety of clinical presentations of ARN have been reported. Most patients are otherwise healthy individuals of either sex and any age. While mild inflammation has been reported as the initial problem, most patients present with a unilateral severe inflamed eye with pain and pronounced loss of vision. Approximately 36% of patients will either present with or ultimately develop bilateral disease (both eyes affected).

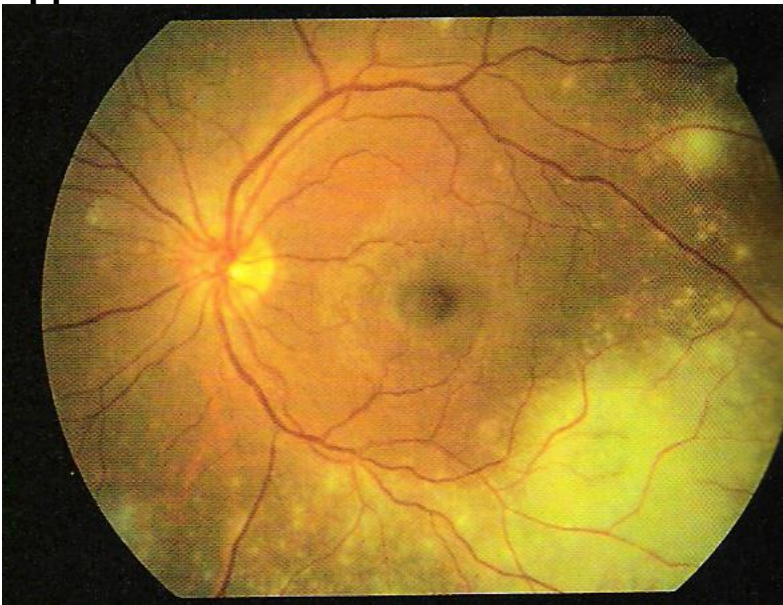
How is ARN diagnosed?

ARN is mostly a clinical diagnosis based on the findings a patient has in the office. The diagnosis is mostly suggested by the finding of severe inflammation of the vitreous (the jelly in the eye) with blockage of arteries nourishing the peripheral retina and death of retinal cells causing the retina to appear white. A typical appearance is shown in the figure below.

Normal Appearance of the Retina



Appearance of the Retina in Acute Retinal Necrosis



Sometimes fluids from the eye are sampled or a spinal tap is done. The fluid sample is sent for laboratory testing (polymerase chain reaction) to detect the presence of viral DNA. Some patients develop the eye problems before, during, or after the development of skin manifestations of a herpes-family virus infection.³ Occasionally, ARN may present with hearing loss or symptoms of meningitis (headaches, back or neck pain).

How is it treated?

Treatment of ARN is a complex issue that is unique for each individual and is dictated by the various complications that develop as a result of the disease. Because of its relative infrequent occurrence, there has never been an organized, controlled, randomized, prospective clinical trial to compare treatment regimens for the disease. Given the link between ARN and viral infections, most cases of ARN are treated with intense intravenous (medication delivered by needle to the vein) antiviral medicines such as acyclovir for 5 to 10 days. High doses are required and kidney function must be monitored closely during the treatment. This is often followed by oral antiviral therapy for up to 6 weeks. Intravitreal antiviral medication (an injection of medication directly into the eye) is sometimes offered as well. Retinal detachments are commonplace after the diagnosis of ARN has been made. Surgical intervention may be advisable either before or after a retinal detachment develops in an attempt to save the eye.

What is the prognosis?

It is well recognized that the diagnosis of ARN carries a poor prognosis. Even with aggressive antiviral therapy, severe visual loss is the norm. One study revealed that even when aggressively treated, 84% of patients developed retinal detachment. In recent series, approximately 50% of patients end with better than 20/200 visual acuity after six months follow-up.³

After reading this information, If you would like to learn more about acute retinal necrosis, an excellent resource is the Pubmed site on the National Library of Medicine web page at the following link:
<http://www.ncbi.nlm.nih.gov/entrez/query.fcgi>.

References

1. Cochrane TF, Silvestri G, McDowell C, et al. Acute retinal necrosis in the United Kingdom: results of a prospective surveillance study. *Eye* 2012;26:370-378.
2. Duker JS, Blumenkranz MS. Diagnosis and management of the acute retinal necrosis (ARN) syndrome. *Surv Ophthalmol* 1991;35:327-343.
3. Browning DJ, Blumenkranz MS, Culbertson WW, Clarkson JD, Tardif Y, Gourdeau A, Minturn J. Association of varicella zoster dermatitis with acute retinal necrosis syndrome. *Ophthalmology* 1987;94:602-606.

Updated 4-20-2017