

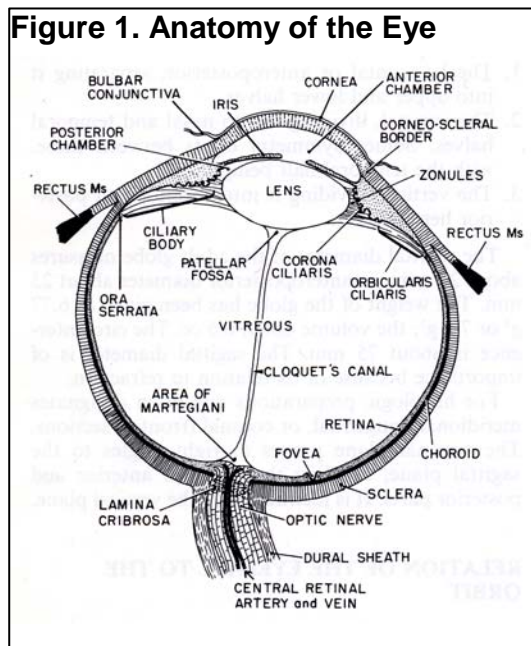
# What You Should Know About Stargardt Disease and Fundus Flavimaculatus

By David J. Browning, MD, PhD

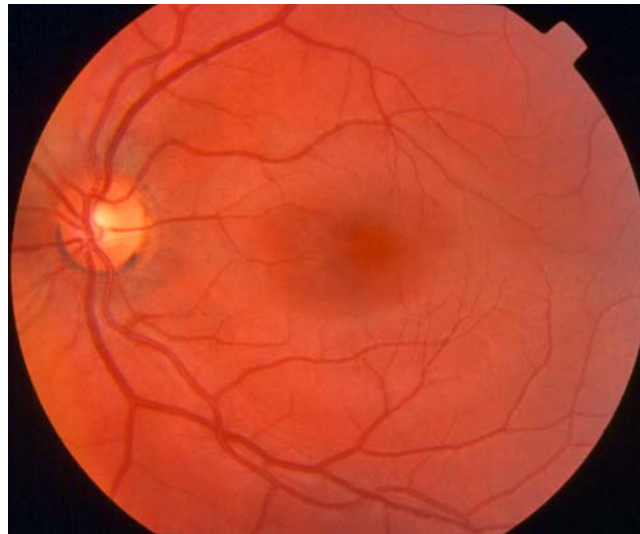Stargardt Disease and fundus flavimaculatus are two genetic diseases of the macula, the central area of the retina, which is the neural lining of the back of the eye. The macula is responsible for reading vision. In Stargardt Disease and fundus flavimaculatus, central reading vision is lost. Peripheral vision and night vision, which are mediated by the extra-macular retina, are unaffected. Both Stargardt Disease and fundus flavimaculatus may have atrophic scars of the macula in advanced stages, and yellow fishtail shaped flecks in the retina. The difference between the diseases has to do with their appearance to the examining doctor.

Advanced Stargardt Disease always has the atrophic macular scar, and may or may not have the flecks. Fundus flavimaculatus always has the yellow flecks and may or may not have the atrophic macular scar. In truth, the two conditions probably describe the same spectrum of genetic mutations, and little is known about why the eye manifestations can appear differently among different patients. To help familiarize the reader, Figure 1 shows the anatomy of the eye. Figure 2 shows a photo of a normal macula. Figure 3 shows an advanced case of Stargardt Disease. Figure 4 shows a case of fundus flavimaculatus.

**Figure 1. Anatomy of the Eye**



**Figure 2. Photo of Normal Macula**



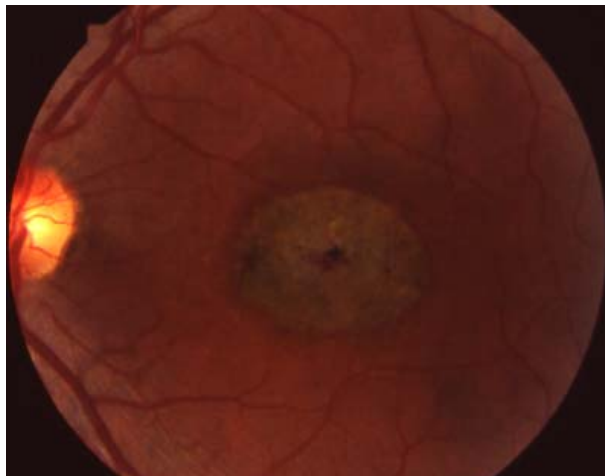
## What Causes These Two Diseases (Which are Probably the Same)?

Both conditions are caused by genetic mutations. Most cases are caused by mutations to the ABCR gene found on chromosome 1. This gene codes for a protein involved in transporting certain molecules into the macular rods. In this form of the

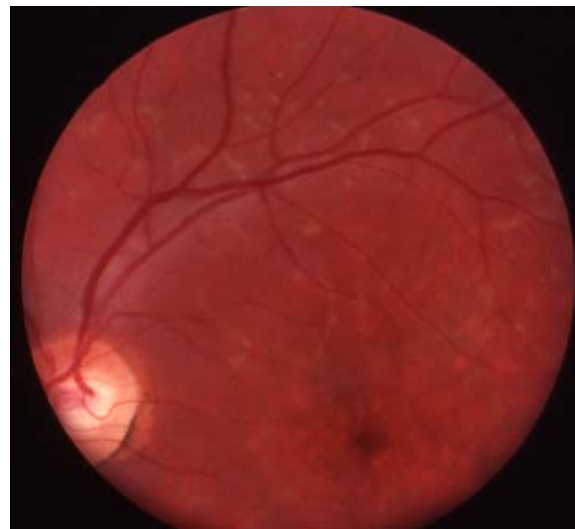disease, two copies of the mutated gene are necessary for the disease to be expressed. That is, most cases of these conditions are autosomal recessive, such that each parent contributes one copy of the mutated gene to the affected child. That is why Stargardt Disease and fundus flavimaculatus are more commonly seen in offspring of parents who are related, such as cousins, for example.

A rarer form of these conditions is autosomal dominant, meaning that it takes only one copy of the mutated gene to cause the disease. The mutations in autosomal dominant Stargardt Disease or fundus flavimaculatus can occur in a certain location in chromosome 13 or in chromosome 6. It is likely that future research will turn up other mutations, which cause conditions that doctors currently diagnose as Stargardt Disease or fundus flavimaculatus. That is, these named diseases actually refer to multiple specific, different causes (genetic mutations), which all lead to similar visual problems and clinical presentations.

**Figure 3. Stargardt Disease**



**Figure 4. Fundus Flavimaculatus**



### **What Can Be Done for These Diseases?**

Although certain of the genetic mutations causing Stargardt Disease and fundus flavimaculatus have been deduced, this knowledge has not translated into effective treatment. Although various vitamin therapies have been attempted, there is no evidence that any therapy yet tried has been beneficial. In particular, the specific combination of vitamins A, C, E, and the minerals zinc and copper, which has been shown to help in age-related macular degeneration, has never been shown to beneficially affect Stargardt Disease or fundus flavimaculatus. Patients are advised to eat a balanced, heart healthy diet and to take a multivitamin, as is every person.

### **How Is This Condition Diagnosed?**

Usually the diagnosis is apparent from the history and the way the eye looks to the examining ophthalmologist. Patients generally begin to lose reading vision in both eyes between the ages of 6 and 28. Initially the eyes may look normal, but as the years

pass, the flecks and atrophic scars develop. A useful test is the fluorescein angiogram in which a vegetable dye is injected into a vein of the arm and a series of photos of the retina are taken. In approximately 86% of patients a sign called the dark choroid is present, which arises from the abnormal accumulation of the substance lipofuscin in the retinal pigment epithelium, a layer of cells under the retina.

### **What is the Prognosis?**

The earlier the onset of the disease, the more likely it is that both eyes will eventually have vision of 20/200 or worse, that is, legally blind. No patient goes completely blind. Once vision begins to blur, the loss of reading vision generally occurs within two years.

There are several reports in which ocular trauma in patients with Stargardt Disease or fundus flavimaculatus have developed extensive subretinal scarring. For this reason, protective goggles are recommended as a routine when playing sports to avoid blows to the eyes.

### **Final Comments**

Stargardt Disease and fundus flavimaculatus together comprise the most common sight threatening retinal dystrophies, making up 7% of this class of disease. Active research is underway to try to find a cure, and patients should be seen yearly to keep abreast of potential advances.

After you read this brochure, we encourage you to browse our website, including the Frequently Asked Questions section and the Forums, where patients may share their experiences with one another. If you have a focused question for which you cannot find an answer, we welcome you to ask Dr. Browning at [www.retinareference.com](http://www.retinareference.com). Also, an excellent resource for medical literature is Pubmed, on the National Library of Medicine website, accessible at [www.pubmed.com](http://www.pubmed.com).