

What You Should Know About Intermediate Uveitis

David J. Browning MD, PhD

Intermediate uveitis is an inflammation of the inside of the eye. The body's immune system attacks certain eye tissues for unknown reasons, and the attacking immune cells cause problems with vision. These cells are called lymphocytes and monocytes and they travel through the bloodstream to invade the eye. They do this by infiltrating the vitreous, the jelly that fills the eye, and releasing chemicals that cause blood vessels in the eye to leak. These inflammatory chemicals also cause scar tissue and sometimes, abnormal blood vessels to

grow inside the eye. Scar tissue can wrinkle the retina, the lining of the back of the eye, distorting vision. The leaky blood vessels cause swelling of the retina, which is known as cystoid macular edema. Sometimes the abnormal blood vessels break and bleed inside the eye, producing a vitreous hemorrhage in which blood mixes with the vitreous jelly and blocks vision. If the inflammation lasts long enough, the lens of the eye may become cloudy, a condition known as a cataract. Figure 1 shows the locations of the parts of the eye we have been discussing.

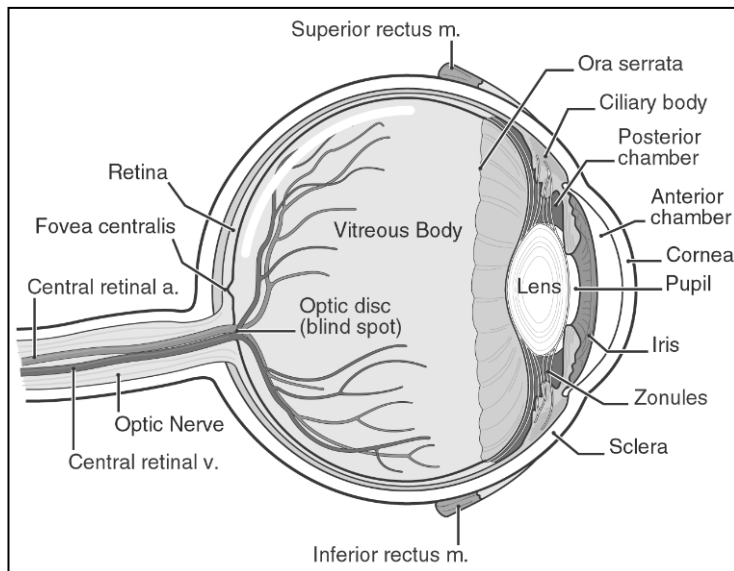


Figure 1. Anatomy of the eye.

Below are a few images that depict what we have discussed so far. Figure 2a shows what the inside of a normal, unaffected eye looks like and 2b shows what the inside of an eye with intermediate uveitis looks like.

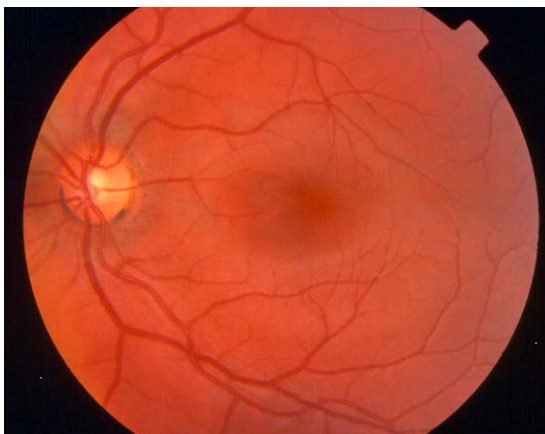


Figure 2a. Normal human eye.

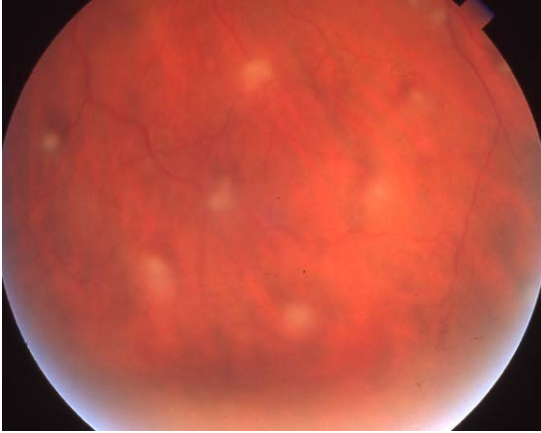


Figure 2b. Intermediate uveitis with puff balls.

Who Is Affected?

Patients affected by intermediate uveitis range in age from 5 –50 years old, with most between the ages of 20 and 30 years old. There is a genetic component to the disease, as identical twins have been reported with it, and genetic markers on the surfaces of cells indicate that patients with certain markers are 3-5 times more likely to develop the disease. These genetic markers, called HLA antigens, are one way our immune system recognizes our own cells from foreign cells. For example, organ transplants work best when these antigens match between donor and recipient. Having certain HLA antigens puts a patient at higher risk for developing intermediate uveitis. Both sexes are affected, and in 80% of patients, both eyes are involved. However, one eye is usually more severely affected than the other.

How is Intermediate Uveitis Diagnosed?

The main method of diagnosis is examination of the eye by an ophthalmologist. This inflammation is detected by the presence of clumps of white cells in the vitreous, white cells (sheathing) lining the vessels of the retina, and swelling of the central retina (macular edema). Sometimes the ophthalmologist can see wrinkled scar tissue on the retinal surface or abnormal blood vessels in the retina, usually near the bottom of the eye. In determining the diagnosis, the ophthalmologist reviews the patient's medical history and may order certain tests to rule out other causes. It is important for the doctor to know about any health conditions, especially multiple sclerosis, since this increases the chance of developing intermediate uveitis. Blood tests may be drawn to make sure the patient is not infected with Syphilis or Lyme disease. Other blood tests including angiotensin converting enzyme (ace) and a complete blood count (cbc) may be drawn. A chest x-ray may be obtained to check for a disease called sarcoidosis, which can mimic intermediate uveitis.

How Is Intermediate Uveitis Treated?

Intermediate uveitis is treated with cortisone or related drugs, which may be prescribed as pills or delivered as a shot beside or even inside the eye. Severe cases are treated with cryotherapy, which is a freezing treatment or laser treatment to the bottom part of the eye. More

severe cases may require an operation called vitrectomy in which the jelly inside the eye is removed. For the most severe cases, immunosuppressive drugs such as methotrexate, azathioprine, infliximab, and adalimumab are given.¹ The complications of intermediate uveitis, such as cataract or a wrinkled scar on the retina, may require operations to correct.

What Happens Without Proper Treatment?

Patients who fail to receive treatment for intermediate uveitis can have permanent visual loss, although it is rare for any patient to go blind. There are many mild cases, which require only serial examinations to look for worsening.

What Is the Follow-up Care?

Patients with intermediate uveitis must be followed for the remainder of their life. If drugs are used, the doses may be slowly reduced over time. Flares of the disease may require periodic shots of cortisone beside the eye. Steroid treatment requires monitoring for side effects, such as induced diabetes mellitus or increased susceptibility to infection.² Patients are educated to watch for signs of multiple sclerosis, since intermediate uveitis can be the first sign of this disease. Signs such as tingling or numbness in the fingers or toes, or sudden visual loss due to optic nerve disease may provide clues leading to brain MRI scanning to check for this diagnosis. Perhaps 90% of patients with intermediate uveitis never develop multiple sclerosis.

What is the Prognosis?

Most cases of intermediate uveitis are mild and leave patients with reading and driving vision for the duration of life. I have never seen a patient blinded by this disease, although such an outcome is possible if care is neglected. With careful follow-up and reasonable compliance with treatments, patients with intermediate uveitis should be able to accomplish their goals and enjoy a good visual quality of life.

After reading about intermediate uveitis here (www.retinareference.com), you can submit questions on the home page at the Contact button. If you wish to pursue further information, an excellent site on the World Wide Web is Pubmed, a site inside the National Library of Medicine web page. This site is at this link:
<http://www.ncbi.nlm.nih.gov/entrez/query.fcgi>.

Document last revised 8-18-2012

References

1. Diaz-Llopis M, Salom D, Garcia-de-Vicuna C, et al. Treatment of refractory uveitis with adalimumab: a prospective multicenter study of 131 patients. *Ophthalmology* 2012;119:1575-1581.
2. Udoetuk JD, Dai Y, Ying GS, et al. Risk of corticosteroid-induced hyperglycemia requiring medical therapy among patients with inflammatory eye diseases. *Ophthalmology* 2012;119:1569-1574.