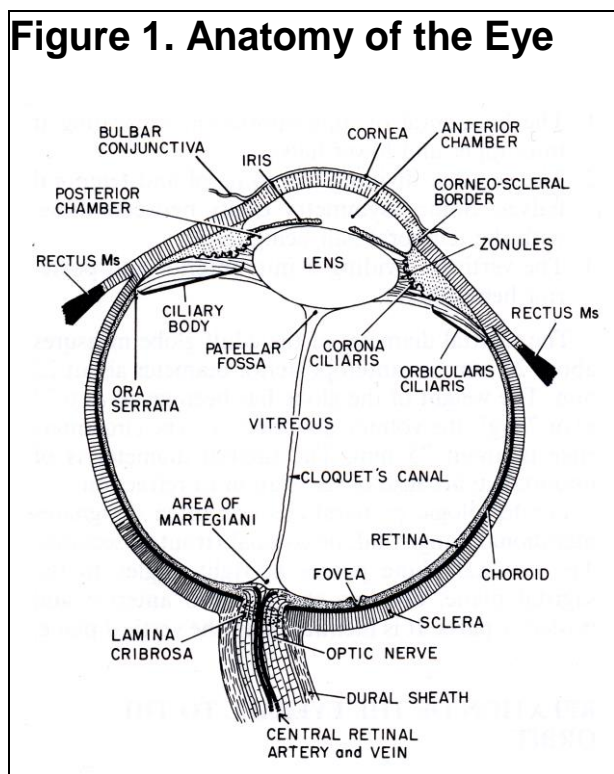


# What You Should Know About Choroidal Hemangiomas

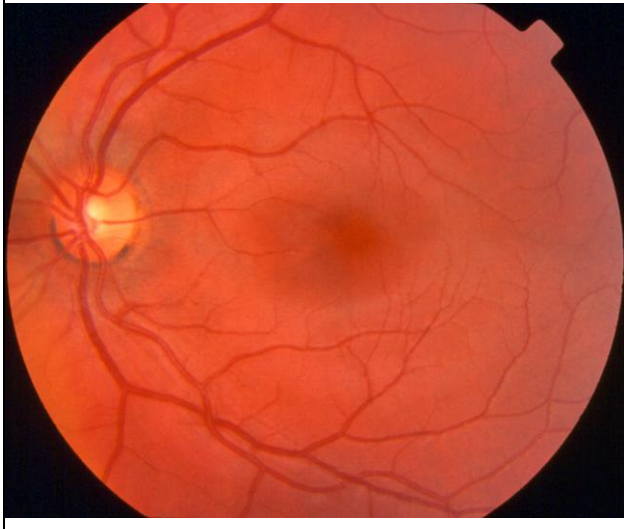
By David J. Browning, MD, PhD

Normal embryonic development is the rule, but occasionally abnormalities occur. When tissue in the human body grows to abnormal prominence in some way, it is called a hamartoma. In the eye, the choroid is the layer of blood vessels under the retina, which lines the back of the eye. Choroidal hemangioma is a developmental abnormality of this layer of blood vessels. It is a hamartoma of blood vessels. The causes for the abnormal development are unknown. We have included a few illustrations to help with visualization of the images and structures we will discuss. Figure 1 shows the layers of tissue lining the back of the eye. Figure 2 shows what the back of the eye looks like to a doctor looking through the pupil. Figure 3 is an example of an eye affected with a choroidal hemangioma.

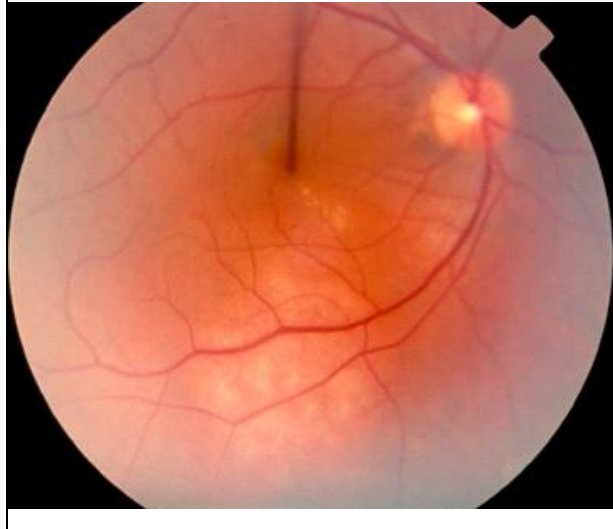**Figure 1. Anatomy of the Eye**



**Figure 2. Normal View Inside the Eye**



**Figure 3. Choroidal Hemangioma**



## **Two Types of Choroidal Hemangiomas**

Choroidal hemangiomas can occur in diffuse and circumscribed types. Diffuse choroidal hemangiomas are broad and flat lesions, which occur in patients with port-wine stains of the facial skin. These patients often have glaucoma, or high pressure in the eye, with diffuse hemangioma. Circumscribed choroidal hemangiomas are an isolated eye condition with no other systemic features. These are smaller, dome-shaped lesions, with better-defined margins than the diffuse type. The two types of hemangiomas are diagnosed at different ages. Diffuse choroidal hemangiomas are usually diagnosed in affected patients before they reach the age of 10, probably because other abnormalities lead to investigation. Circumscribed choroidal hemangiomas are diagnosed later, on average in the age range 40 - 50. These are rare, with symptomatic circumscribed choroidal hemangiomas occurring in one patient in 2,500,000 per year.

## **Symptoms and Signs of Choroidal Hemangiomas**

Both types of choroidal hemangiomas can cause blurred vision from a number of secondary problems. Choroidal hemangiomas can cause fluid leakage under the retina (serous retinal detachment), swelling of the retina tissue (cystoid edema), and growth of scar tissue and additional abnormal blood vessels below or on the surface of the retina. Oddly enough, abnormal bone growth can rarely develop in a choroidal hemangioma. All of these symptoms generally occur gradually and painlessly.

## **Treatment of Choroidal Hemangiomas**

Asymptomatic choroidal hemangiomas do not need to be treated, but should be observed periodically to detect potential problems that could arise. If serous retinal detachment or retinal edema occurs with symptoms, various treatments may be useful, including argon laser, transpupillary thermotherapy, radioactive iodine-125 plaque therapy, and photodynamic therapy with verteporfin infusion. Each treatment has its own relative benefits and indications. Probably photodynamic therapy with verteporfin infusion offers the fewest side effects.

## **Special Tests Used**

There are a number of tests a retina specialist may order to rule out alternative diagnoses. Choroidal hemangiomas can masquerade as metastatic cancer from a primary source elsewhere, or a primary choroidal melanoma, or other eye diseases. Ultrasonography is a test used to determine the height of the lesion and its sound wave reflectivity. Fluorescein or indocyanine green angiography involve an infusion of approximately 5ml (1 teaspoon) of colored dye into a vein of the arm, followed by a series of time-lapse photographs of the eye as the dye circulates through the blood vessels.

## **Final Comments**

Choroidal hemangiomas, though uncommon, generate more concern than many conditions because they can cause serious vision loss in the young. With accurate diagnosis and timely treatment, much can be done to prevent vision loss. However, sometimes vision loss is unavoidable. This is especially possible if the hemangioma underlies the center of the retina called the macula, where the finest visual acuity arises.

After you read this document, if you have further questions, please visit my website at [www.retinareference.com](http://www.retinareference.com). Another excellent resource for medical literature is Pubmed, on the National Library of Medicine website, accessible at [www.pubmed.com](http://www.pubmed.com).

Updated 3/23/2018